

LINAC-based stereotactic radiosurgery to the brain with concurrent vemurafenib for melanoma metastases

Kamran A. Ahmed · Jessica M. Freilich · Sarah Sloot · Nicholas Figura · Geoffrey T. Gibney · Jeffrey S. Weber · Siriporn Sarangkasiri · Prakash Chinnaiyan · Peter A. Forsyth · Arnold B. Etame · Nikhil G. Rao

Received: 18 September 2014 / Accepted: 11 December 2014 / Published online: 18 December 2014
© Springer Science+Business Media New York 2014

Abstract While selective BRAF inhibitors have demonstrated improved outcomes in patients with metastatic BRAF V600E mutant melanoma, management of brain metastases prior to and during therapy presents challenges. Stereotactic radiosurgery (SRS) is an effective treatment for melanoma brain metastases, but there is limited safety and efficacy data on the use of SRS during BRAF therapy. An analysis was performed of patients with metastatic melanoma and brain metastases treated with SRS while on vemurafenib. MRI scans were reviewed post-SRS to evaluate local control (LC) as well as distant control. We identified 80 metastatic melanoma brain lesions treated in 24 patients. The median planning target volume was 0.28 cm³ (range 0.05–4.19 cm³), and lesions were treated to a median dose of 24 Gy (range 15–24 Gy). The median follow up was 5.1 months (range 2–25.2 months). Eight (10 %) lesions showed progression at a median of 6.1 months (range 2–20.1 months) following

SRS. Kaplan–Meier LC estimates at 6 and 12 months were 92 and 75 %, respectively. Fourteen (58 %) patients were noted to have distant brain failure at a median of 3.4 months (range 1.9–16.1 months) following treatment with SRS. Median overall (OS) from the date of SRS was 7.2 months (range 1.5–26.8 months) with a median of 11.9 months (range 1.5–28.5 months) since the date of brain metastases diagnosis. There was no evidence of increased toxicity with the combination of SRS and vemurafenib. SRS to brain metastases appears to be both safe and effective for patients treated concurrently with BRAF inhibitors.

Keywords Stereotactic radiotherapy · Vemurafenib · Brain metastases · Stereotactic radiosurgery

Introduction

Progression of intra-cranial disease is the most frequent cause of death in patients with melanoma metastases [1, 2]. Metastatic disease to the brain from melanoma has a poor prognosis with a median survival of 3–5 months [1]. Approximately 40–60 % of cutaneous melanoma patients harbor the BRAF mutation which results in the constitutive activation of the serine–threonine protein kinase B-RAF (BRAF) and the downstream mitogen-activated protein kinase (MAPK) pathway [3, 4]. Ninety percent of activating exon 15 BRAF mutations occur at the V600 codon (predominantly V600E). Vemurafenib is a selective inhibitor of BRAF V600E, as well as other RAF kinases, leading to inhibition of the MAPK pathway, inhibition of cellular proliferation, cell cycle arrest, and apoptosis [5]. In a randomized phase III trial of metastatic melanoma patients whose disease harbored the BRAF V600E mutation, vemurafenib improved overall response rates, progression-

K. A. Ahmed (✉) · J. M. Freilich · S. Sarangkasiri · P. Chinnaiyan · N. G. Rao (✉)
Department of Radiation Oncology, H. Lee Moffitt Cancer Center and Research Institute, 12902 Magnolia Dr., Tampa, FL 33612, USA
e-mail: kamran.ahmed@moffitt.org

N. G. Rao
e-mail: nikhil.rao.md@flhosp.org

S. Sloot · G. T. Gibney · J. S. Weber
Department of Cutaneous-Oncology, H. Lee Moffitt Cancer Center and Research Institute, Tampa, FL 33612, USA

N. Figura
Morsani College of Medicine, University of South Florida, Tampa, FL 33612, USA

P. A. Forsyth · A. B. Etame
Department of Neuro-Oncology, H. Lee Moffitt Cancer Center and Research Institute, Tampa, FL 33612, USA

free survival, and overall survival (OS) when compared to dacarbazine [6].

A phase II trial was reported by Long et al. of dabrafenib, a BRAF kinase inhibitor [7]. The authors reported an approximately 40 and 30 % intracranial response rate in patients with previously untreated and treated metastases, respectively. The response of brain metastases to vemurafenib appears encouraging [8, 9]. Results from 24 metastatic melanoma patients in an open label trial were recently reported [9]. Seven (37 %) patients achieved >30 % intracranial tumor regression, and three (16 %) patients achieved a partial response. There has been hesitation to combine vemurafenib with radiation treatment to the brain due to case reports noting increased skin toxicity [10–12]. Narayana et al. reported initial results of 12 patients treated with stereotactic radiosurgery (SRS) or whole brain radiation treatment (WBRT) prior to or along with vemurafenib [13] and Gaudy-Marqueste et al. recently reported on 53 gamma knife radiosurgeries (GKRS) performed prior to or alongside vemurafenib or dabrafenib in 30 patients [14]. In this study, we assess our results in the combined treatment of vemurafenib and LINAC based SRS for melanoma brain metastases.

Methods and materials

Between March 2010 and November 2013 a total of 80 consecutive lesions in 24 patients with the V600E mutation were treated with concurrent vemurafenib dosed to 960 mg two times a day. Patients were instructed to hold the drug for 2–3 days before and after SRS treatment. Patients were followed until May 2014. The records for these patients were retrospectively reviewed. The study was approved by our Institutional Review Board (IRB).

SRS technique

Metastases were defined using magnetic resonance imaging (MRI) (Siemens Sonata, Siemens Medical Systems, Erlangen, Germany) with 1 mm slices for treatment planning purposes prior to the delivery of radiation. The MRI image was co-registered and fused with computed tomography (CT) imaging (General Electric Medical System, Milwaukee, WI). A uniform 1 mm expansion of the gross tumor volume (GTV) was used to create the planning target volume (PTV). All lesions were treated in a single fraction. Doses were prescribed to ensure coverage of at least 95 % of the PTV with the prescription dose. Dose selection was based on the size of the lesion according to RTOG criteria [15]. Dose level reductions were performed based on proximity to critical structures and plan conformity.

Constraints placed on SRS planning included max point doses of ≤ 8 Gy to the optic nerves and optic chiasm and ≤ 16 Gy to the brainstem. Treatments were delivered using multiple dynamic conformal arcs or intensity modulated radiotherapy (IMRT). Patient immobilization was achieved by using a commercially available head mask fixation system (Brainlab AG, Feldkirchen, Germany). Treatments were delivered with the BrainLab Novalis Classic LINAC with 6 MV photons. Imaging was provided with the BrainLab Exac Trac positioning system.

Follow-up

Patients in this study were followed with examinations by the treating radiation oncologist, neurosurgeon, or medical oncologist with MRI imaging at 2–3 month intervals. At each visit neurologic status was assessed. Toxicity of treatment was assessed by the Radiation Therapy Oncology Group (RTOG) grading system. Local failure was defined as a 20 % radiographic increase in the size of the previously irradiated area according to RECIST criteria version 1.1 [16]. Distant brain failure was defined as new brain metastases or leptomeningeal enhancement outside the previously irradiated volume. The primary endpoint for this study was local failure. Secondary endpoints included distant brain failure, OS, and toxicity of treatment, and were calculated from the date of treatment to the event date.

Statistical analysis

Statistical analyses were performed using JMP 11 (SAS Institute Inc, Cary, NC, USA). Descriptive statistics were used to summarize the cohort including median and range for continuous variables or counts and percentages for categorical variables. The OS, local control (LC), and distant brain control (DC) rates were calculated from the date of treatment to the date of death or progression using the Kaplan–Meier method. A two-tailed $p < 0.05$ was considered statistically significant.

Results

Patient and lesion characteristics

Patient characteristics are summarized in Table 1. The median age of patients was 58.5 years (range 21–88) and the majority of patients were male ($n = 19$; 79.2 %). Seven patients were treated with cytotoxic chemotherapy prior to starting vemurafenib. In addition, prior to starting treatment with vemurafenib, one patient was treated with interleukin-2, 8 patients received ipilimumab, 6 patients received a MEK inhibitor, and 2 patients received anti-PD1

Table 1 Patient characteristics

| Variable | n | % |
|------------------------------------|-------|------|
| No. of patients | 24 | |
| No. of lesions | 80 | |
| No. of lesions treated per patient | | |
| Median | 2.5 | |
| Range | 1–13 | |
| Age (years) | | |
| Median | 58.5 | |
| Range | 21–88 | |
| Gender | | |
| Male | 19 | 79.2 |
| Female | 5 | 20.8 |
| KPS % | | |
| 100 | 7 | 29.2 |
| 90 | 12 | 50.0 |
| 80 | 5 | 20.8 |
| DS GPA | | |
| 1 | 9 | 37.5 |
| 1.5 | 9 | 37.5 |
| 2 | 6 | 25.0 |
| No. of metastases at presentation | | |
| Multiple | 17 | 70.8 |
| Single | 7 | 29.2 |

KPS Karnofsky performance score, DS-GPA diagnosis specific graded prognostic assessment score

therapy. No patients presented with metastases to the brain at the time of initial melanoma presentation. Seven patients (29.2 %) were treated for a single site of metastases while 17 patients (70.8 %) were treated to multiple sites of metastases (range 2–6).

Lesion characteristics are summarized in Table 2. The median follow-up for all lesions following SRS was 5.1 months (range 2–25.2 months) with a follow-up of 6.3 months (range 2.4–26.8 months) following brain metastases diagnosis. Total treatment dose was 15 Gy in 3 lesions (3.8 %), 16 Gy in 1 lesion (1.3 %), 18 Gy in 14 lesions (17.5 %), 20 Gy in 1 lesion (1.3 %), 21 Gy in 23 lesions (28.8 %), and 24 Gy in 38 lesions (47.5 %). The median time from start of vemurafenib to SRS treatment was 5.2 months (range 0.4–17.1 months).

Local and distant brain control

Eight lesions were found to undergo local failure. Rates of 6 and 12 month LC for all lesions were 92 and 75 %, Fig. 1. Of the patients who experienced local failure, median time to event was 6.1 months (range 2–20.1 months) post SRS.

Fourteen patients (58 %) were found to undergo distant brain failure on follow-up imaging. In these patients,

Table 2 Lesion characteristics

| Variable | n | % |
|---|-----------|------|
| FU from SRS | | |
| Median (months) | 5.1 | |
| Range (months) | 2–25.2 | |
| FU from brain metastases diagnosis | | |
| Median (months) | 6.3 | |
| Range (months) | 2.4–26.8 | |
| Interval between start of vemurafenib and SRS | | |
| Median (months) | 5.2 | |
| Range (months) | 0.4–17 | |
| GTV | | |
| Median (cm ³) | 0.1 | |
| Range (cm ³) | 0.01–2.6 | |
| PTV | | |
| Median (cm ³) | 0.28 | |
| Range (cm ³) | 0.05–4.19 | |
| Diameter (mm) | | |
| Median | 6.5 | |
| Range | 2.6–20 | |
| Dose | | |
| 15 Gy | 3 | 3.8 |
| 16 Gy | 1 | 1.3 |
| 18 Gy | 14 | 17.5 |
| 20 Gy | 1 | 1.3 |
| 21 Gy | 23 | 28.8 |
| 24 Gy | 38 | 47.5 |
| Location of metastases | | |
| Basal ganglia | 2 | 2.5 |
| Cerebellum | 9 | 11.3 |
| Frontal | 34 | 42.5 |
| Occipital | 5 | 6.3 |
| Parietal | 14 | 17.5 |
| Temporal | 15 | 18.8 |
| Thalamus | 1 | 1.3 |

GTV gross tumor volume, PTV planning target volume

distant brain failure occurred at a median of 3.4 months (range 1.9–16.1 months) following treatment with SRS. Nine of these patients (64 %) failed while on treatment with vemurafenib. Rates of 6 and 12 month DC for all patients were 45 and 23 %, respectively, as seen in Fig. 2. Of the patients who experienced distant brain failure, 6 received whole brain radiation therapy and 5 patients received further SRS to new sites of metastases.

Overall survival

Fifteen patients (62.5 %) were dead at the time of study analysis. Median OS from the date of SRS was 7.2 months

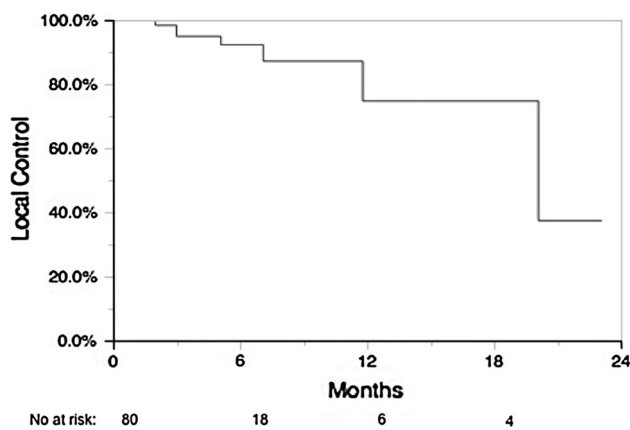


Fig. 1 Local control in all patients

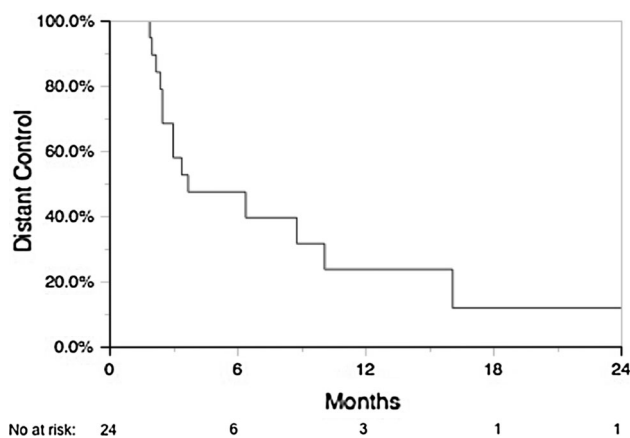


Fig. 2 Distant brain control in all patients

(range 1.5–26.8 months) with a median of 11.9 months (range 1.5–28.5 months) since the date of brain metastases diagnosis. There was a trend towards improved survival and greater diagnosis specific graded prognostic assessment (DS-GPA); OS rates at 6 and 12 months were 61 and 38 % for class 1–1.5 and 100 and 83 % for class 2 ($p = 0.07$).

Toxicity

There was no evidence of scalp reactions or skin toxicity after SRS in our treated cohort. Two months following treatment, one patient was noted to have a seizure in a previously treated temporal lobe metastases. MRI imaging revealed hemorrhage and the patient was taken to the OR for surgical resection. Pathology revealed tumor recurrence and radiation necrosis. In addition, one patient was noted to have grade 1 headaches after SRS and was prescribed steroids. One additional patient experienced grade 1 fatigue and vertigo following treatment, which subsided 1 week following treatment. There was no evidence of grade 3 or greater radiation toxicity noted.

Discussion

In this study of vemurafenib with SRS for the treatment of melanoma brain metastases, we note several findings. First, good LC is achieved in the combined treatment of vemurafenib with SRS. However, many patients failed distantly with a 12 month DC rate of 23 %. Finally, SRS appears to be a safe treatment modality when combined with vemurafenib with low rates of toxicity noted in our patient cohort.

Randomized trials have shown a proven benefit to the treatment of extracranial disease with vemurafenib. A phase II trial of 132 patients showed that when using vemurafenib alone an extracranial response rate of 53 % [95 % confidence interval (CI) 44–62 %; 6 % with a complete response and 47 % with a partial response] can be achieved [17]. The median OS of patients in the trial was 15.9 months. A phase III randomized clinical trial was conducted comparing vemurafenib with dacarbazine in 675 patients with previously untreated, metastatic melanoma with the BRAF V600E mutation [6]. OS was reported to be 84 % in the vemurafenib group and 64 % in the dacarbazine group at 6 months. Vemurafenib was associated with a relative reduction of 63 % in the risk of death and of 74 % in the risk of either death or disease progression, as compared with dacarbazine.

With improved extracranial systemic control, rates of intracranial control have become increasingly important in the management of metastatic melanoma. The response of vemurafenib for metastatic disease in the brain appears encouraging. Recently, results from an open label trial of 24 metastatic melanoma patients with non-resectable, previously treated brain metastases was reported [9]. Median progression-free survival and OS was 3.9 and 5.3 months, respectively. Seven (37 %) patients achieved >30 % intracranial tumor regression, and three (16 %) patients achieved a confirmed partial response. Vemurafenib was well tolerated with grade 3 AE reported in 4 patients. Mixed results have been reported in single institution case reports and series in the response of brain metastases with vemurafenib [18, 19]. A phase II trial is currently open and assessing the efficacy and safety of vemurafenib in previously treated and untreated brain metastases (clinicaltrials.gov: NCT01378975).

There has been caution in combining vemurafenib with radiation treatment due to fears of increased toxicity. Studies have revealed a radiosensitization effect with vemurafenib [20] and several case reports have reported increased skin toxicity. Radiation recall dermatitis has been reported in a previously irradiated area as well as scalp reactions in patients treated with WBRT [5, 10–12, 21]. However, with the treatment of vemurafenib alone, cutaneous sequelae such as squamous cell carcinomas, keratosis pilaris-like eruptions, seborrheic dermatitis-like rashes, hand–foot skin reaction,

and photosensitivity have been reported [6, 22]. While a synergistic effect may theoretically lead to increased toxicity with the combined treatment of vemurafenib and radiation, no significant skin reactions or unexpected toxicities were noted in our patient cohort. The current treatment paradigm at our institution is to hold vemurafenib for 2–3 days before and after SRS treatment, due to the risks of presumed synergistic toxicity. Prospective studies are ongoing to assess the safety and efficacy of concurrent radiotherapy and vemurafenib (clinicaltrials.gov: NCT02145910).

Narayana et al. reported on outcomes in 12 patients who received WBRT or SRS prior to or alongside vemurafenib [13]. With a median follow-up of 12.2, 6 months LC, freedom from new brain lesions and OS was reported as 75, 57, and 92 %. The distant brain failure rate was reported as 58.3 %, with a median time to failure of 14.5 months. In addition, Gaudy-Marqueste et al. reported on 53 gamma knife radiosurgeries (GKRS) performed in 30 patients receiving vemurafenib or dabrafenib [14]. In 33 GKRS there was concurrent BRAF inhibition, four of these were with a transient break and in the remaining 20 BRAF inhibition took place after GKRS. A >20 % increase in volume was noted in 13 % of treated lesions. Similar to our LINAC-based SRS cohort treated with concurrent vemurafenib, minimal treatment toxicity was noted.

LC of lesions was fairly high in our study with results that appear slightly better than those of patients treated with SRS alone for melanoma brain metastases [23–25]. This may indicate a synergistic effect between BRAF inhibitors and SRS. The 6 month distant control of about 45 % in our study is comparable to reports from Narayana et al. and slightly better than a median of 12.9 weeks for a new brain metastases reported by Gaudy-Marqueste et al. Both local and distant failures in our study occurred not only after SRS but vemurafenib treatment as well. OS was 11.9 months from the date of brain metastases diagnosis in our cohort, indicating a possible correlation between extracranial systemic control with vemurafenib and effective radiosurgery treatment to the brain. The limitations of this study include its retrospective nature with a diverse patient cohort, which was heavily pretreated with multiple systemic agents. In addition, a variety of dosing strategies were used for SRS treatment to differing locations within the brain.

In conclusion, this study reports findings on the treatment of brain metastases with SRS with concurrent vemurafenib. DC rates appear similar to previously reported series of patients with melanoma brain metastases treated with vemurafenib. We report high rates of LC for patients treated with vemurafenib and SRS. In addition, there were no reports of increased skin or other toxicities noted in our patient cohort indicating SRS is a safe management option in the combined treatment of melanoma brain metastases who are also receiving vemurafenib.

Conflict of interest The authors declare that they have no conflicts of interest.

References

1. Staudt M, Lasithiotakis K, Leiter U, Meier F, Eigentler T, Bamberg M, Tatagiba M, Brossart P, Garbe C (2010) Determinants of survival in patients with brain metastases from cutaneous melanoma. *Br J Cancer* 102:1213–1218. doi:10.1038/sj.bjc.6605622
2. Hwu WJ, Lis E, Menell JH, Panageas KS, Lamb LA, Merrell J, Williams LJ, Krown SE, Chapman PB, Livingston PO, Wolchok JD, Houghton AN (2005) Temozolomide plus thalidomide in patients with brain metastases from melanoma: a phase II study. *Cancer* 103:2590–2597. doi:10.1002/cncr.21081
3. Curtin JA, Fridlyand J, Kageshita T, Patel HN, Busam KJ, Kutzner H, Cho KH, Aiba S, Brocker EB, LeBoit PE, Pinkel D, Bastian BC (2005) Distinct sets of genetic alterations in melanoma. *N Engl J Med* 353:2135–2147. doi:10.1056/NEJMoa050092
4. Davies H, Bignell GR, Cox C, Stephens P, Edkins S, Clegg S, Teague J, Woffendin H, Garnett MJ, Bottomley W, Davis N, Dicks E, Ewing R, Floyd Y, Gray K, Hall S, Hawes R, Hughes J, Kosmidou V, Menzies A, Mould C, Parker A, Stevens C, Watt S, Hooper S, Wilson R, Jayatilake H, Gusterson BA, Cooper C, Shipley J, Hargrave D, Pritchard-Jones K, Maitland N, Chenevix-Trench G, Riggins GJ, Bigner DD, Palmieri G, Cossu A, Flanagan A, Nicholson A, Ho JW, Leung SY, Yuen ST, Weber BL, Seigler HF, Darrow TL, Paterson H, Marais R, Marshall CJ, Wooster R, Stratton MR, Futreal PA (2002) Mutations of the BRAF gene in human cancer. *Nature* 417:949–954. doi:10.1038/nature00766
5. Bollag G, Hirth P, Tsai J, Zhang J, Ibrahim PN, Cho H, Spevak W, Zhang C, Zhang Y, Habets G, Burton EA, Wong B, Tsang G, West BL, Powell B, Shellooe R, Marimuthu A, Nguyen H, Zhang KY, Artis DR, Schlessinger J, Su F, Higgins B, Iyer R, D'Andrea K, Koehler A, Stumm M, Lin PS, Lee RJ, Grippo J, Puzanov I, Kim KB, Ribas A, McArthur GA, Sosman JA, Chapman PB, Flaherty KT, Xu X, Nathanson KL, Nolop K (2010) Clinical efficacy of a RAF inhibitor needs broad target blockade in BRAF-mutant melanoma. *Nature* 467:596–599. doi:10.1038/nature09454
6. Chapman PB, Hauschild A, Robert C, Haanen JB, Ascierto P, Larkin J, Dummer R, Garbe C, Testori A, Maio M, Hogg D, Lorigan P, Lebbe C, Jouary T, Schadendorf D, Ribas A, O'Day SJ, Sosman JA, Kirkwood JM, Eggermont AM, Dreno B, Nolop K, Li J, Nelson B, Hou J, Lee RJ, Flaherty KT, McArthur GA, Group BS (2011) Improved survival with vemurafenib in melanoma with BRAF V600E mutation. *N Engl J Med* 364:2507–2516. doi:10.1056/NEJMoa1103782
7. Long GV, Trefzer U, Davies MA, Kefford RF, Ascierto PA, Chapman PB, Puzanov I, Hauschild A, Robert C, Algazi A, Mortier L, Tawbi H, Wilhelm T, Zimmer L, Swartzky J, Swann S, Martin AM, Guckert M, Goodman V, Streit M, Kirkwood JM, Schadendorf D (2012) Dabrafenib in patients with Val600Glu or Val600Lys BRAF-mutant melanoma metastatic to the brain (BREAK-MB): a multicentre, open-label, phase 2 trial. *Lancet Oncol* 13:1087–1095. doi:10.1016/S1470-2045(12)70431-X
8. Kefford RMM, Arance A, Nathan P, Blank C, Francoise MA, Gonzalez R, Schachter J, Margolin K, Lasserre SF, Veronese L, McArthur G Vemurafenib (2013) Metastatic melanoma patients with brain metastases: an open-label, single-arm, phase 2, multicenter study. In: 10th international meeting of the Society for Melanoma Research, Philadelphia
9. Dummer R, Goldinger SM, Turtschi CP, Eggmann NB, Michielin O, Mitchell L, Veronese L, Hilfiker PR, Felderer L, Rinderknecht JD (2014) Vemurafenib in patients with BRAF(V600) mutation-

- positive melanoma with symptomatic brain metastases: final results of an open-label pilot study. *Eur J Cancer* 50:611–621. doi:[10.1016/j.ejca.2013.11.002](https://doi.org/10.1016/j.ejca.2013.11.002)
10. Anker CJ, Ribas A, Grossmann AH, Chen X, Narra KK, Akerley W, Andtbacka RH, Noyes RD, Shrieve DC, Grossmann KF (2013) Severe liver and skin toxicity after radiation and vemurafenib in metastatic melanoma. *J Clin Oncol* 31:e283–e287. doi:[10.1200/JCO.2012.44.7755](https://doi.org/10.1200/JCO.2012.44.7755)
 11. Boussemart L, Boivin C, Claveau J, Tao YG, Tomasic G, Routier E, Mateus C, Deutsch E, Robert C (2013) Vemurafenib and radiosensitization. *JAMA Dermatol* 149:855–857. doi:[10.1001/jamadermatol.2013.4200](https://doi.org/10.1001/jamadermatol.2013.4200)
 12. Schulze B, Meissner M, Wolter M, Rodel C, Weiss C (2014) Unusual acute and delayed skin reactions during and after whole-brain radiotherapy in combination with the BRAF inhibitor vemurafenib. Two case reports. *Strahlenther Onkol* 190:229–232. doi:[10.1007/s00066-013-0474-3](https://doi.org/10.1007/s00066-013-0474-3)
 13. Narayana A, Mathew M, Tam M, Kannan R, Madden KM, Golfinos JG, Parker EC, Ott PA, Pavlick AC (2013) Vemurafenib and radiation therapy in melanoma brain metastases. *J Neurooncol* 113:411–416. doi:[10.1007/s11060-013-1127-1](https://doi.org/10.1007/s11060-013-1127-1)
 14. Gaudy-Marqueste C, Carron R, Delsanti C, Loundou A, Monestier S, Archier E, Richard MA, Regis J, Grob JJ (2014) On demand Gamma-knife strategy can be safely combined with BRAF-inhibitors for the treatment of melanoma brain metastases. *Ann Oncol*. doi:[10.1093/annonc/mdu266](https://doi.org/10.1093/annonc/mdu266)
 15. Shaw E, Scott C, Souhami L, Dinapoli R, Kline R, Loeffler J, Farnan N (2000) Single dose radiosurgical treatment of recurrent previously irradiated primary brain tumors and brain metastases: final report of RTOG protocol 90-05. *Int J Radiat Oncol Biol Phys* 47:291–298
 16. Eisenhauer EA, Therasse P, Bogaerts J, Schwartz LH, Sargent D, Ford R, Dancey J, Arbuck S, Gwyther S, Mooney M, Rubinstein L, Shankar L, Dodd L, Kaplan R, Lacombe D, Verweij J (2009) New response evaluation criteria in solid tumours: revised RECIST guideline (version 1.1). *Eur J Cancer* 45:228–247. doi:[10.1016/j.ejca.2008.10.026](https://doi.org/10.1016/j.ejca.2008.10.026)
 17. Sosman JA, Kim KB, Schuchter L, Gonzalez R, Pavlick AC, Weber JS, McArthur GA, Hutson TE, Moschos SJ, Flaherty KT, Hersey P, Kefford R, Lawrence D, Puzanov I, Lewis KD, Amaravadi RK, Chmielowski B, Lawrence HJ, Shyr Y, Ye F, Li J, Nolop KB, Lee RJ, Joe AK, Ribas A (2012) Survival in BRAF V600-mutant advanced melanoma treated with vemurafenib. *N Engl J Med* 366:707–714. doi:[10.1056/NEJMoa1112302](https://doi.org/10.1056/NEJMoa1112302)
 18. Rochet NM, Dronca RS, Kottschade LA, Chavan RN, Gorman B, Gilbertson JR, Markovic SN (2012) Melanoma brain metastases and vemurafenib: need for further investigation. *Mayo Clin Proc* 87:976–981. doi:[10.1016/j.mayocp.2012.07.006](https://doi.org/10.1016/j.mayocp.2012.07.006)
 19. Rochet NM, Kottschade LA, Markovic SN (2011) Vemurafenib for melanoma metastases to the brain. *N Engl J Med* 365:2439–2441. doi:[10.1056/NEJMc1111672](https://doi.org/10.1056/NEJMc1111672)
 20. Sambade MJ, Peters EC, Thomas NE, Kaufmann WK, Kimple RJ, Shields JM (2011) Melanoma cells show a heterogeneous range of sensitivity to ionizing radiation and are radiosensitized by inhibition of B-RAF with PLX-4032. *Radiother Oncol* 98:394–399. doi:[10.1016/j.radonc.2010.12.017](https://doi.org/10.1016/j.radonc.2010.12.017)
 21. Harding JJ, Barker CA, Carvajal RD, Wolchok JD, Chapman PB, Lacouture ME (2014) Cutis verticis gyrata in association with vemurafenib and whole-brain radiotherapy. *J Clin Oncol* 32:e54–e56. doi:[10.1200/JCO.2013.49.3528](https://doi.org/10.1200/JCO.2013.49.3528)
 22. Huang V, Hepper D, Anadkat M, Cornelius L (2012) Cutaneous toxic effects associated with vemurafenib and inhibition of the BRAF pathway. *Arch Dermatol* 148:628–633. doi:[10.1001/archdermatol.2012.125](https://doi.org/10.1001/archdermatol.2012.125)
 23. Mori Y, Kondziolka D, Flickinger JC, Kirkwood JM, Agarwala S, Lunsford LD (1998) Stereotactic radiosurgery for cerebral metastatic melanoma: factors affecting local disease control and survival. *Int J Radiat Oncol Biol Phys* 42:581–589
 24. Seung SK, Sneed PK, McDermott MW, Shu HK, Leong SP, Chang S, Petti PL, Smith V, Verhey LJ, Wara WM, Phillips TL, Larson DA (1998) Gamma knife radiosurgery for malignant melanoma brain metastases. *Cancer J Sci Am* 4:103–109
 25. Selek U, Chang EL, Hassenbusch SJ 3rd, Shiu AS, Lang FF, Allen P, Weinberg J, Sawaya R, Maor MH (2004) Stereotactic radiosurgical treatment in 103 patients for 153 cerebral melanoma metastases. *Int J Radiat Oncol Biol Phys* 59:1097–1106. doi:[10.1016/j.ijrobp.2003.12.037](https://doi.org/10.1016/j.ijrobp.2003.12.037)